

**The following resources related to this article are available online at [www.sciencemag.org](http://www.sciencemag.org) (this information is current as of November 16, 2009 ):**

**Updated information and services**, including high-resolution figures, can be found in the online version of this article at:

<http://www.sciencemag.org/cgi/content/full/312/5776/999c>

A list of selected additional articles on the Science Web sites **related to this article** can be found at:

<http://www.sciencemag.org/cgi/content/full/312/5776/999c#related-content>

This article **cites 6 articles**, 2 of which can be accessed for free:

<http://www.sciencemag.org/cgi/content/full/312/5776/999c#otherarticles>

This article has been **cited by** 1 articles hosted by HighWire Press; see:

<http://www.sciencemag.org/cgi/content/full/312/5776/999c#otherarticles>

This article appears in the following **subject collections**:

Technical Comments

[http://www.sciencemag.org/cgi/collection/tech\\_comment](http://www.sciencemag.org/cgi/collection/tech_comment)

Information about obtaining **reprints** of this article or about obtaining **permission to reproduce this article** in whole or in part can be found at:

<http://www.sciencemag.org/about/permissions.dtl>

# Response to Comment on “The Brain of LB1, *Homo floresiensis*”

Dean Falk,<sup>1\*</sup> Charles Hildebolt,<sup>2</sup> Kirk Smith,<sup>2</sup> M. J. Morwood,<sup>3</sup> Thomas Sutikna,<sup>4</sup> Jatmiko,<sup>4</sup> E. Wayhu Saptomo,<sup>4</sup> Barry Brunnsden,<sup>2</sup> Fred Prior<sup>2</sup>

Martin *et al.* claim that they have two endocasts from microcephalics that appear similar to that of LB1, *Homo floresiensis*. However, the line drawings they present as evidence lack details about the transverse sinuses, cerebellum, and cerebral poles. Comparative measurements, actual photographs, and sketches that identify key features are needed to draw meaningful conclusions about Martin *et al.*'s assertions.

Martin *et al.*'s (1) efforts to show that LB1's cranial capacity cannot be attributed to intraspecific dwarfing in *Homo erectus* suggest that Falk *et al.* (2) claimed otherwise. However, Falk *et al.* documented that LB1's cranial capacity is too small to be attributed to normal dwarfing of *H. erectus* and further showed that its relative brain size is consistent with those of apes/australopithecines (Fig. 1). It would therefore be surprising if LB1's relative brain size scaled like a dwarfed elephant, for example, leading us to question the aptness of table 1 and figure 1 presented by Martin *et al.*

As noted in (2), the virtual endocast of the microcephalic in question was prepared from a skull cast reposit in the American Museum of Natural History (AMNH), and Falk *et al.* scaled the virtual endocasts of all comparative specimens to match LB1's volume (417 cm<sup>3</sup>) to facilitate shape comparisons. We have since reanalyzed the CT data and determined a capacity of 276 cm<sup>3</sup> for the microcephalic (3). Although the AMNH was unable to provide a recorded age for the microcephalic, its anomalous teeth suggested to us that it might be a juvenile, and we are happy to learn that it is, in fact, from a 10-year-old male.

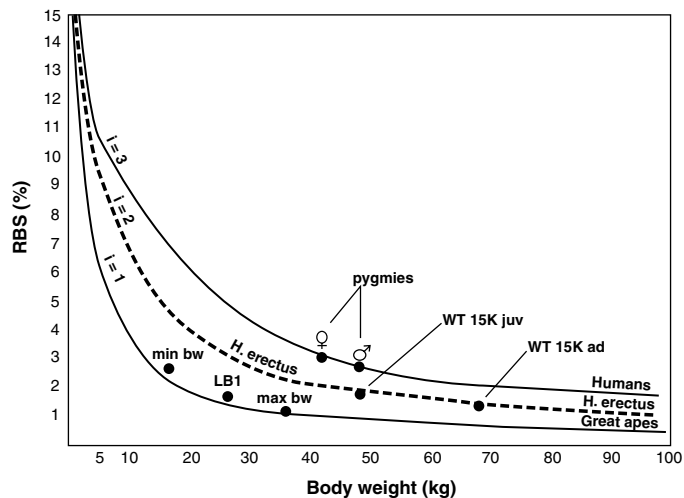
Contrary to Martin *et al.*, we did not assume that there is only one type of primary microcephaly, as detailed in the text of our supporting online material (2). Martin *et al.* claim that there are more than 400 genetic syndromes associated with primary microcephaly that “typically have autosomal recessive inheritance.” This conflicts with our reading of the literature. Rather than being associated with primary microcephaly, small head size “defined as an

occipitofrontal circumference that is at or below –2 standard deviations (SD) at birth...constitutes a feature found in more than 400 genetic syndromes” (4), and these 400 syndromes are not portrayed as generally uniform nor of known genetic inheritance (4). Our more restrictive definition of microcephaly (2) is therefore warranted, especially in discussions pertaining to LB1, because adult primary microcephalics typically have a brain volume of about 400 cm<sup>3</sup> (4).

Martin *et al.* further argue that because LB1 was an adult, comparison with microcephalics should focus on high-functioning types (which can survive to adulthood) and that Jakob

Moegele's early death renders comparison inappropriate. On the contrary, “early death” in low-functioning microcephalics is defined as “death that typically occurs within the first several years of life” [table 1 in (4)]. Because Jakob Moegele lived to be 10, one cannot rule out that he may have been a high-functioning primary microcephalic. Martin *et al.* were indeed fortunate to locate a 32-year-old female microcephalic, because by that age 78% of female microcephalics are estimated to have died (5). Because of brain shrinkage, one would also not expect to obtain a highly convoluted endocast (like LB1's) from such a specimen (5, 6), and we gather from the lack of detail on Martin *et al.*'s line drawings that neither of their microcephalics reproduced endocasts that are highly convoluted. As illustrated in (6), Jakob Moegele's virtual endocast is shaped remarkably like that of endocasts from other microcephalics, rather than like that from LB1 as claimed (7), and we are glad to have a microcephalic specimen of its size and age in the sample of microcephalics that we are currently investigating.

The weight of Martin *et al.*'s comment is their assertion that they have identified one hemicast and one complete endocast from microcephalics that appear similar to LB1's. However, the line drawings they provide lack crucial details about the transverse sinuses and frontal and occipital poles [figure 2 in (1)]. Although the authors provide a line drawing for LB1's skull, no image is provided for its endocast. A line drawing is provided for an endocast of a microcephalic from the Field Museum, but not for its skull, which, as described (and illustrated in actual photographs) in the reference cited by Martin *et al.*, “is long-headed and narrow, with a lowly vault, the face narrow, with ape-like protrusion of the jaws” (8). This skull differs starkly from LB1's, which is extremely brachycephalic (2, 9). Providing drawings of one hemicast and one endocast from microcephalics and asserting that they look like the virtual endocast from LB1 without illustrating the latter is therefore inadequate.



**Fig. 1.** Cranial capacity in cubic centimeters as a percentage of body weight in grams (RBS, relative brain size) plotted against body weight (kg) for humans and apes (10). Indices (*i*) describe apelike RBS (*i* = 1) and RBS that are twice (*i* = 2) and three times (*i* = 3) those expected for apes of equivalent body weights. Congo pygmies are placed on the human curve at their mean body weights of 42 kg and 48 kg for 319 women and 405 men, respectively (11). The curve for *H. erectus* is hypothetical because it is based on data showing that *i* = 2 from only one available skeleton (KNM-WT 15000). Estimated juvenile and adult weights for WT 15000 are 48 kg and 68 kg, respectively, and juvenile and adult cranial capacities are 880 and 909 cm<sup>3</sup>, respectively (12). LB1's cranial capacity of 417 cm<sup>3</sup> places it on or near the ape curve at its minimum, mean, and maximum body weight estimates (16 to 36 kg, mean 26 kg) (9), which is consistent with data from australopithecines. Figure and legend from figure S1 in (2).

<sup>1</sup>Department of Anthropology, Florida State University, Tallahassee, FL 32306, USA. <sup>2</sup>Mallinckrodt Institute of Radiology, Washington University School of Medicine, St. Louis, MO 63110, USA. <sup>3</sup>Archaeology and Palaeoanthropology, University of New England, Armidale, New South Wales 2351, Australia. <sup>4</sup>Indonesian Centre for Archaeology, Jl. Raya Condet Pejaten No. 4, Jakarta 12001, Indonesia.

\*To whom correspondence should be addressed. E-mail: dfalk@fsu.edu

Comparative measurements along with actual photographs of the microcephalic hemicast and endocast should be compared with published images of LB1's endocast in frontal, occipital, lateral, and dorsal views (2) and accompanied by corresponding sketches that identify key features, such as the transverse sinuses and cerebellum, similar to Falk *et al.* (2, 6). Without this evidence, the assertions of Martin *et al.* remain unsubstantiated and difficult to address in further detail.

#### References and Notes

1. R. D. Martin *et al.*, *Science* **312**, 999 (2006); [www.sciencemag.org/cgi/content/full/312/5776/999b](http://www.sciencemag.org/cgi/content/full/312/5776/999b).
2. D. Falk *et al.*, *Science* **308**, 242 (2005).
3. Reported by D. Falk *et al.* in a talk for the African Genesis meetings, Johannesburg, South Africa, January 13, 2006.
4. S. L. Gilbert, W. B. Dobyns, B. T. Lahn, *Nat. Rev. Genet.* **6**, 581; [10.1038/nrg1634](https://doi.org/10.1038/nrg1634) (2005).
5. M. A. Hofman, *J. Neurol.* **231**, 87 (1984).
6. D. Falk *et al.*, *Science* **310**, 236c (2005).
7. J. Weber, A. Czarnetzki, C. Pusch, *Science* **310**, 236 (2005).
8. E. G. Dru-Drury, *Trans. R. Soc. S. Afr.* **8**, 149 (1919/1920).
9. P. Brown *et al.*, *Nature* **431**, 1055 (2004).
10. A. H. Schultz, *Primatologica* **1**, 887 (1956).
11. V. Pennetti, L. Sgaramella-Zonta, P. Astolfi, in *African Pygmies*, L. L. Cavalli-Sforza, Ed. (Academic Press, New York, 1986), pp. 127–138.
12. A. Walker, R. Leakey, *The Nariokotome Homo Erectus Skeleton* (Harvard Univ. Press, Cambridge, 1993).
13. We thank the National Geographic Society (grants 7769-04 and 7897-05) for supporting this work and anonymous referees for helpful comments.

2 February 2006; accepted 20 April 2006  
 10.1126/science.1124972